



Haematological and Hepatological effects of Pito, Burukutu-Guinea corn and Burukutu-Millet in Albino Rats

Chinedu Imo*, Richard-Harris N. Boyi, Bassey Victor Nsan
& Adamu Emmanuel Williams

Department of Biochemistry, Faculty of Pure and Applied Sciences,
Federal University Wukari, Taraba State, Nigeria.
chinedu04@yahoo.com

Received: 17.05.2020 Accepted: 10.06.2020
Date of Publication: June, 2020

Abstract: This study investigated the haematological and hepatological effects of selected locally brewed beers in albino rats. Three locally brewed beers were purchased from locally brewed beer joint in Wukari, Nigeria. Twenty male albino rats were used and were randomly distributed into four groups of five rats each. Group 1 served as normal control, while groups 2, 3 and 4 were administered pito, burukutu-Guinea corn and burukutu-millet (10mL/kg bwt) respectively for 21 days before being sacrificed. Result showed that ALT and AST activities increased in all the groups administered the different beer compared to the control. Cholesterol increased in group 2, but decreased in group 4. Potassium and glucose reduced in all test groups compared to the normal control. The differences in cholesterol, potassium and glucose levels are statistically less-significant ($p > 0.05$) compared to the control. The liver histoarchitectural state of the test animals administered the beers compared to the control animals showed the beers had toxic effect on the animals. There is evidence of infiltration and distortion of some regions of the liver tissue in the test animals. This agrees with the results of serum biochemical parameters evaluated. The WBC, LYM and GRA increased in group 3 and reduced in groups 2 and 4 compared to the control. The MID reduced in all the test groups compared to the control. RBC, Hb and HCT increased in all the test groups compared to the control. The MCV increased only in group 4 and decreased in

groups 2 and 3. The MCH, MCHC and RDWc reduced in all the test groups, while PLT, PCT, MPV and PDWc increased in all the test groups compared to the control. This study has shown that constant administration of pito, burukutu-guinea corn and burukutu-millet in the test animals for a long duration caused alterations and negative effect on the liver function, but may not interfere negatively with the Hb and RBC count.

Keywords: Burukutu-guinea corn, burukutu-millet, haematological, liver tissue, pito.

Introduction

Burukutu is a popular alcoholic beverage of vinegar-like flavour, consumed mainly in the northern region of Nigeria, in the republic of Benin, and in Ghana. It is produced mainly from the grains of guinea corn of the species *Sorghum vulgare* and *Sorghum bicolor* [1] and millet. Preparation of burukutu involves steeping, germination, fermentation and maturation [2]. The resulting product is a cloudy alcoholic beverage called burukutu. Burukutu contains almost all essential amino acids in required proportion except cysteine and tryptophan which are being completely destroyed by heat during boiling [3].

Traditionally, burukutu is brewed with red or white sorghum variety and/or maize malts [4]. It has a sour taste resulting from the action of the lactic acid bacteria (*Lactobacillus spp.*) and opaque colour because of suspended solid and yeast materials [5, 6] with thin consistency. The production process of burukutu is time consuming, complex and sometimes carried out under unhygienic conditions. Back slopping (the addition of an old fermented batch of a previous brew to serve as an inoculum) is usually done to hasten the fermentation process. Burukutu has a very short shelf-life and is expected to be consumed within five days after back

slopping. It can however stay much longer (about a week or two) if not back slopped, and tightly covered. Souring of the left-over beverage after five days is usually over combed by mixing it with a freshly prepared one to make it fresh again for consumption.

Pito is a traditionally brewed alcoholic beverage. It is produced mainly from the grains of guinea corn (*Sorghum vulgare* or *Sorghum bicolor*) and millet [1]. Pito brewing is serving as a lucrative business particularly for the rural folks. It is produced traditionally by malting, mashing, fermentation and maturation of the grains which are steeped in water over night, after which excess water is drained. Pito is golden yellow to dark brown in colour, with taste varying from slightly sweet to sour. It has been observed that, pure cultures of microorganism can be used to reduced fermentation time and improve production process of the pito [7]. Such pure cultures include *Lactobacillus plantarum* in combination with *Saccharomyces cerevisiae* and *Pediococcus halophilus* in combination with *Candida tropicalis* [7]. The pH, colour, titrable acidity, alcohol content, specific gravity, taste and flavour of Pito produced by use of pure culture can be compared favourably with that produced using the traditional method [7]. Compared with European beers,

pito is heavier and darker, but less bitter [2]. It is mostly neither bottled nor canned, but purchased directly from the household in which it is brewed. It is typically served in a calabash or bottle outside the producer's home where benches are provided for the consumers to sit on and enjoy the beverage. Meanwhile, it has been observed that this beverage can be processed, bottled and stored for 2 months with little or no effect on its characteristics and qualities [8]. Nevertheless, fresh samples of pito have been accepted as better than the stored ones in terms of both microbiological and nutritional quality [9, 10]. All the health risks commonly associated with overconsumption of alcoholic beverages [11] also apply to the misuse of pito.

Documented information on the effects of these locally brewed beers is few and thus, very little research has been done to understand how these locally brewed beers affects some body organs such as the liver. The present study is therefore designed to investigate the effect of these liquors in albino rats. The results of this study will help provide information on the probable effects of these selected locally brewed beers on haematological and liver function indices of consumers and the general public.

Materials and Methods

Duration and year of study

This study was carried out from the month of March to July, 2018 in Wukari, Nigeria.

Procurement of the Beers

The burukutu-millet, burukutu-guinea corn and pito used in this study were purchased from locally brewed beer

joint in Wukari, Taraba State, Nigeria. The beers were properly identified and labeled accordingly. The procurement of the beers was done on a two-days interval and administered fresh, while the remnants was kept in the refrigerator for not more than 48 hours. The beers are believed to be rich in carbohydrates, proteins, fat, crude fibre, iron and calcium.

Experimental Animals

Twenty healthy male albino rats of 8 weeks of age, weighing between 94g-125g used for this study were procured from the animal house Department of Animal production, National Veterinary Research Institute (NVRI) Vom, Plateau State, Nigeria and transferred to the animal house Department of Biochemistry, Federal University Wukari, Taraba State, Nigeria. The animals were allowed to acclimatize for fourteen days prior to the experiment.

Experimental Design

The animals were randomly placed into four groups of 5 animals each. Group 1 served as normal control, while groups 2, 3 and 4 served as test animals. The animals were allowed access to feed and water *ad libitum*. The animals were kept in a well-ventilated wired cage after which their body weights were measured accordingly before the start of the feeding regiment. Standard laboratory protocols for animal studies were maintained as approved by the Department of Biochemistry, Faculty of Pure and Applied Sciences, Federal University Wukari, Nigeria. Group 1 animals served as normal control and did not receive any beer; group 2 animals were administered pito (10mL/kg bwt); group 3 animals were

URL: <http://journals.covenantuniversity.edu.ng/index.php/cjpl>

administered burukutu-guinea corn (10mL/kg bwt), while group 4 animals were administered burukutu-millet (10mL/kg bwt). The beers were administered for twenty-one days through oral route.

Blood Collection

After administration of the beers, the animals were sacrificed after overnight fasting. The animals were anaesthetized with chloroform; incisions were made into their thoracic cavity and blood samples collected by cardiac puncture using a 10mL hypodermic syringe and dispensed into two different types of tubes. The first part of the blood was dispensed into an anti-coagulant containing sample tube for haematological analysis. The second part of the blood was dispensed into a very cleaned plain tube and allowed to clot for fifteen minutes and centrifuged for 10 minutes at 4000 rpm. Serum was separated from the clot using pasteur pipette for the serum biochemical analysis.

Biochemical and Histological Analysis

Serum biochemical analysis was carried out on each sample. The biochemical parameters selected were Aspartate transaminase (AST), Alanine transaminase (ALT), Cholesterol,

glucose and Potassium. These were determined using an auto-analyzer (Reflotron Plus). The haematological parameters were analysed using an auto-analyser (Abacus 380 haematological auto-analyzer). The auto analyzers were switched on and allowed to calibrate. Each of the Samples (tubes) was placed directly into the sample carrier slot of the auto analyzer, the sample was identified by simple ID given by the operator. The tests were set and the analyzer aspirates the samples. Once the sample is processed, the measurements and results are displayed. The liver of all the animals were harvested and examined histologically (Stain: Haematoxylin & Eosin). Photomicrographs of liver sections of the rats were taken and examined.

Statistical Analysis

The biochemical results were subjected to statistical analysis using the One-Way Analysis of Variance (ANOVA) and further with Duncan Multiple Comparisons using Statistical Package for Social Science (SPSS) version 21. The means were compared for significance at $p \leq 0.05$ and the group results were presented as mean \pm standard deviation ($n=5$).

Results

Table 1: Concentration of selected liver function indices in rats administered Pito, Burukutu-Guinea corn and Burukutu-millet

Parameters	Group 1 (Normal control)	Group 2 (Pito 10mL/Kg bw)	Group 3 (Burukutu-Guinea corn 10mL/Kg bw)	Group 4 (Burukutu-millet 10mL/Kg bw)
ALT(IU/L)	55.87 ± 6.31 ^a	69.40 ± 17.04 ^{a,b}	74.23 ± 1.19 ^b	69.20 ± 1.04 ^{a,b}
AST (IU/L)	249.67 ± 16.50 ^a	255.00 ± 22.72 ^a	271.67 ± 35.64 ^a	328.33 ± 35.02 ^b
Cholesterol (mmol/L)	2.62 ± 0.04 ^a	2.65 ± 0.10 ^a	2.62 ± 0.06 ^a	2.59 ± 0.00 ^a
Potassium (mmol/L)	5.91 ± 0.76 ^a	4.91 ± 0.19 ^a	5.41 ± 0.65 ^a	5.58 ± 0.36 ^a
Glucose (mmol/L)	5.61 ± 1.96 ^a	5.10 ± 1.26 ^a	4.93 ± 0.34 ^a	4.93 ± 1.20 ^a

Result represent mean ± standard deviation of group serum result obtained (n=5).

Means in the same row, having different letters of the alphabet are statistically significant (p<0.05).

Result showed that ALT increased in all the groups administered the different beers compared to the control. AST also

increased in all the groups administered the different beer compared to control. Cholesterol increased in group 2, but decreased in group 4. Potassium and glucose decreased in all the test groups compared to the normal control. The differences in cholesterol, potassium and glucose are statistically less-significant (Table 1).

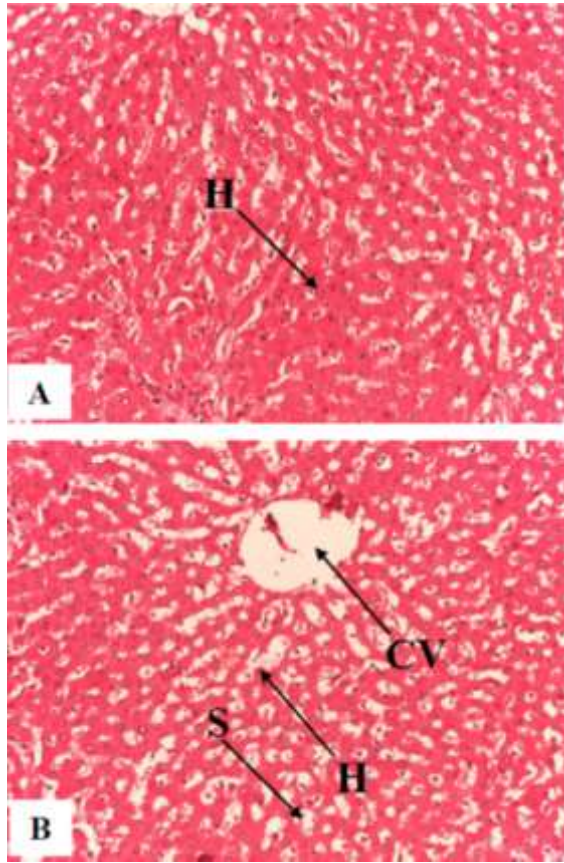


Figure 1: Photomicrographs of liver sections from rat in group 1 (normal control).

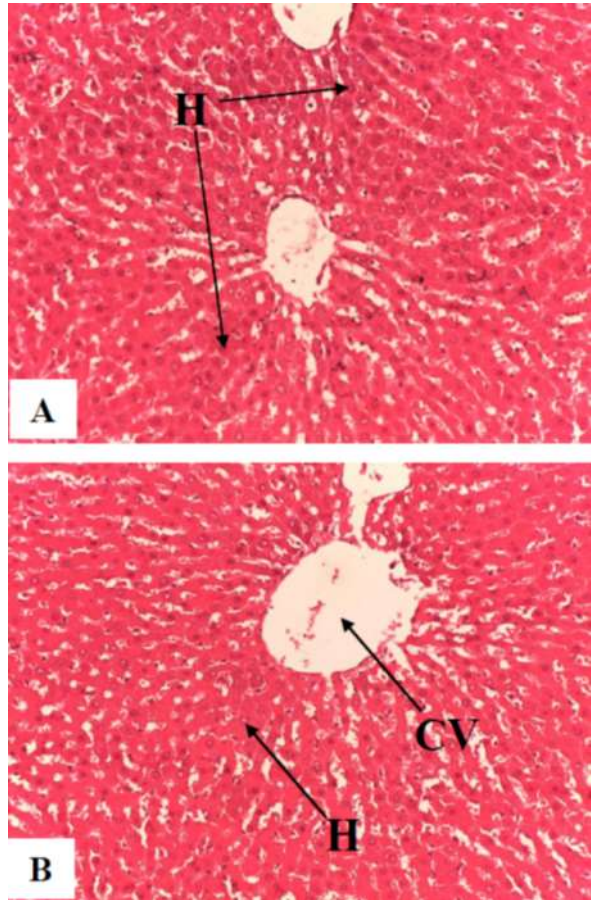


Figure 2: Photomicrographs from liver sections of rat administered Pito (10mL/Kg bw).

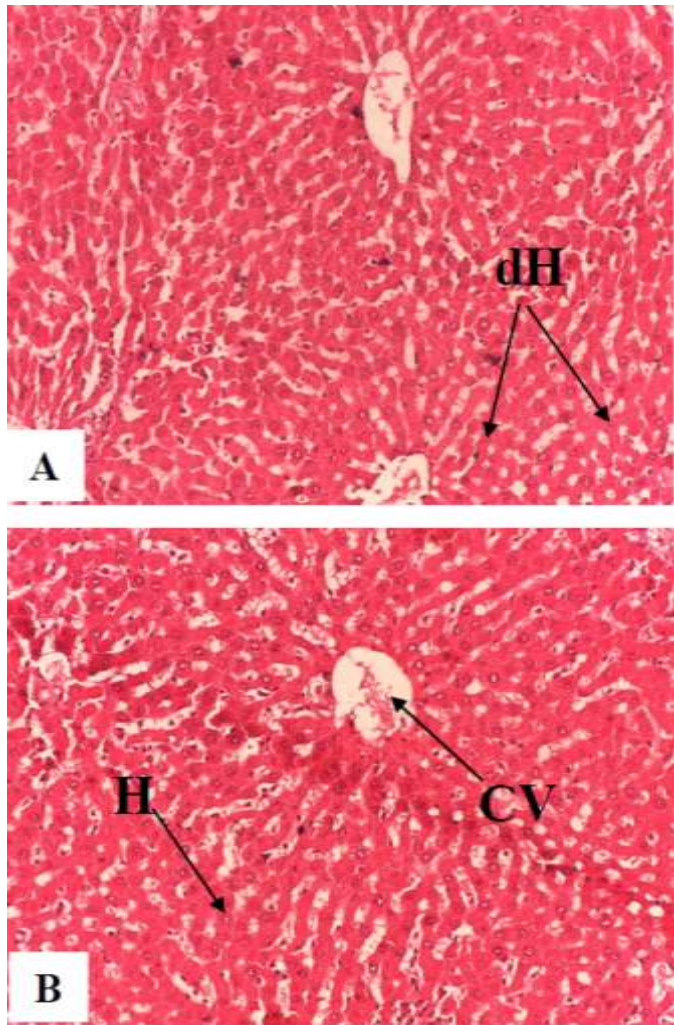


Figure 3: Photomicrographs from liver sections of rat administered Burukutu-Guinea corn (10mL/Kg bw).

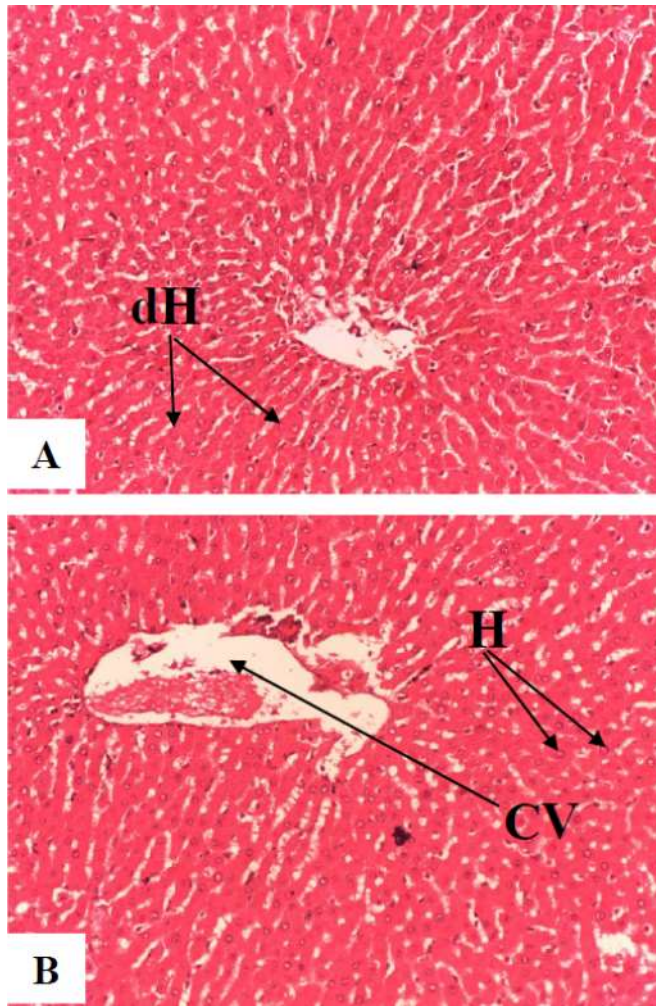


Figure 4: Photomicrographs from liver sections of rat administered Burukutu-millet (10mL/Kg bw).

Table 2: Concentrations of white blood cells ($10^9/L$) in rats administered Pito, Burukutu-Guinea corn and Burukutu-millet

Parameters	Group 1 (Normal control)	Group 2 (Pito 10mL/Kg bw)	Group 3 (Burukutu- Guinea corn 10mL/Kg bw)	Group 4 (Burukutu- millet 10mL/Kg bw)
WBC	10.07 ± 4.81 ^a	6.99 ± 1.52 ^a	10.72 ± 2.69 ^a	6.61 ± 2.34 ^a
LYM	6.97 ± 3.92 ^a	4.87 ± 1.23 ^a	7.00 ± 1.82 ^a	4.06 ± 1.33 ^a
MID	1.37 ± 0.48 ^a	0.74 ± 0.04 ^a	1.34 ± 0.63 ^a	0.96 ± 0.76 ^a
GRA	1.84 ± 0.52 ^{a,b}	1.39 ± 0.35 ^a	2.38 ± 0.30 ^b	1.58 ± 0.26 ^a

Result represent mean ± standard deviation of group serum result obtained (n=5).

Means in the same row, having different letters of the alphabet are statistically significant ($p < 0.05$).

Key: WBC= white blood cell; LYM= lymphocyte; MID= mid-size cells; GRA= granulocyte.

Result showed that WBC, LYM and GRA increased in group 3 and reduced in groups 2 and 4 compared to the control (group 1). The MID reduced in all the groups compared to the control. The alterations that exist in all the groups for all the parameters are not statistically significant ($p > 0.05$) compared with the control (Table 2).

Table 3: Concentrations of RBC, Hb and HCT in rats administered Pito, Burukutu-Guinea corn and Burukutu-millet

Parameters	Group 1 (Normal control)	Group 2 (Pito 10mL/Kg bw)	Group 3 (Burukutu-Guinea corn 10mL/Kg bw)	Group 4 (Burukutu-millet 10mL/Kg bw)
RBC ($10^{12}/L$)	7.05 ± 0.88 ^a	8.61 ± 0.19 ^{b,c}	9.02 ± 0.55 ^c	7.71 ± 0.51 ^{a,b}
Hb (g/dl)	12.47 ± 1.06 ^a	14.17 ± 0.12 ^b	14.73 ± 0.83 ^b	13.20 ± 0.96 ^{a,b}
HCT (%)	39.84 ± 4.31 ^a	45.98 ± 1.28 ^{a,b}	49.08 ± 4.04 ^b	43.79 ± 4.11 ^{a,b}
MCV (fl)	56.33 ± 1.15 ^{a,b}	53.33 ± 0.58 ^c	54.33 ± 1.15 ^{a,c}	56.67 ± 1.53 ^b
MCH (pg)	17.73 ± 0.60 ^a	16.50 ± 0.36 ^{b,c}	16.33 ± 0.12 ^c	17.13 ± 0.32 ^{a,b}
MCHC (g/dl)	31.37 ± 0.81 ^a	30.87 ± 0.76 ^a	30.10 ± 0.90 ^a	30.23 ± 0.71 ^a
RDW _c (%)	22.27 ± 0.49 ^a	21.70 ± 1.05 ^a	22.03 ± 0.75 ^a	20.77 ± 0.67 ^a

Result represent mean \pm standard deviation of group serum result obtained (n=5).

Means in the same row, having different letters of the alphabet are statistically significant (p<0.05).

Key: RBC= red blood cell; Hb= haemoglobin; HCT= hematocrit; MCV= mean corpuscular volume; MCH= mean corpuscular haemoglobin; MCHC=

mean corpuscular haemoglobin concentration; RDWc= red blood cell distribution width count.

Result showed that RBC, Hb and HCT increased in all the test groups compared to the control. The MCV increased only in group 4 and decreased in groups 2 and 3. The MCH, MCHC and RDWc reduced in all the test groups compared to the control (Table 3).

Table 4: Concentration of platelets in rats administered Pito, Burukutu-Guinea corn and Burukutu-millet

Parameters	Group 1 (Normal control)	Group 2 (Pito 10mL/Kg bw)	Group 3 (Burukutu-Guinea corn 10mL/Kg bw)	Group 4 (Burukutu-millet 10mL/Kg bw)
PLT (10 ⁹ /L)	443.33 \pm 48.26 ^a	625.00 \pm 86.69 ^b	521.67 \pm 27.59 ^{a,b}	456.33 \pm 65.13 ^a
PCT (%)	0.32 \pm 0.06 ^a	0.51 \pm 0.09 ^b	0.42 \pm 0.04 ^{a,b}	0.37 \pm 0.08 ^a
MPV (fl)	8.00 \pm 0.85 ^a	8.13 \pm 0.32 ^a	8.07 \pm 0.35 ^a	8.10 \pm 0.44 ^a
PDWc (%)	34.60 \pm 1.91 ^a	35.67 \pm 0.95 ^a	36.13 \pm 1.33 ^a	34.93 \pm 1.27 ^a

Result represent mean \pm standard deviation of group serum result obtained (n=5).

Means in the same row, having different letters of the alphabet are statistically significant (p<0.05).

Key: PLT= platelet; PCT= plateletcrit; MPV= mean platelet volume; PDWc= platelet distribution width count.

Result showed that PLT, PCT, MPV and PDWc increased in all the test groups compared to the control. The increase in PLT and PCT in group 2 is statistically significant (p<0.05) compared to the control. The alterations that exist in all the test groups for MPV and PDWc are not statistically significant (p>0.05) compared with the control (Table 4).

Discussion

The administration of pito, burukutu-guinea corn and burukutu-millet to the test animals caused changes in the

serum activities of AST and ALT. The increase in ALT activity of the test groups showed that consumption of the three different beers for the duration used in this study could cause hepatic toxicity. This is because increase in the activities of liver-maker enzymes such as ALT and AST is used in accessing liver health. A comparative analysis of the serum activity of ALT in the three test groups showed that administration of burukutu-guinea corn caused a significant increase compared to the control, while administration of pito and burukutu-millet caused a less-significant increase (p>0.05). The highest elevation of ALT activity in the group administered the burukutu-guinea corn showed it may have the ability to cause liver alteration or damage in its consumers more than pito and burukutu made from millet. The regular administration of the beers may be causing the enzymes to leak out of the

liver into the blood. This negative effect is one of the health risks commonly associated with overconsumption of alcoholic beverages [11]. Kukoyi *et al.* [12] in their similar research reported that regular consumption of red wine for a long period of time may have the ability of interfering with some liver functions. The administration of red wine in their research caused an elevation of serum ALT and AST activities in albino rats. This agrees with the result of this present study.

The result of AST activity showed that administration of burukutu-millet caused a significant increase ($p < 0.05$) when compared to the control, while administration of pito and burukutu-guinea corn caused a less-significant increase ($p > 0.05$). This increase in all the test groups support the result of ALT, thereby confirming evidence of hepatic toxicity in all the test animals. This showed that individuals who consume these beers regularly for a long period of time are liable to have elevated serum AST and ALT which is an indication of liver toxicity. Cellular leakage of AST and ALT into the blood have been reported to occur due to malfunctioning of cell membrane of some organs [13, 14], such as the liver. However, the highest elevation of AST in group 4 animals administered burukutu-millet showed that it is possible that beside the liver, it may be affecting another organ that may predominantly contain AST, such as the kidney, heart and brain.

Cholesterol level was not significantly altered in all the test animals. Cholesterol level increased less-significantly ($p > 0.05$) in the animals

administered pito, but reduced less-significantly in the animals administered burukutu-guinea corn and burukutu-millet (Table 1). Cholesterol is a precursor of other steroids and an important constituent of the cell membrane and bile acids [15, 16]. This showed that consumption of the three different beers may not cause any apparent alteration of cholesterol level. It therefore means that though the beers altered AST and ALT levels, they may not be able to cause the incidence that may lead to hyperlipidaemia or atherosclerosis. Elevated serum cholesterol and LDL-cholesterol have been reported to constitute risk factors in the development of diseases such as cardiovascular problem. During the transport of cholesteryl esters deposition in the blood vessels, hardening and narrowing of the vessels may result which could result to cardiovascular diseases, especially atherosclerosis [17-19].

Serum glucose level reduced less-significantly ($p > 0.05$) in all the groups administered the beers when compared to the control. However, the result showed the beers have a mild potency of reducing the serum glucose level. Potassium level reduced less-significantly ($p > 0.05$) in all the groups administered the beers when compared to the control. Potassium is known to be in the intracellular fluid and has been reported by Nurminen *et al.* [20] to be among the protective electrolytes against hypertension. The less-significant decrease in potassium level of the animals administered the beers when compared with the control animals is an indication that some

membrane channels may possibly be mildly protected or stabilized. The mild reduction of potassium levels agrees with the reduction of AST and ALT levels in the test animals.

The liver histoarchitectural state of the test animals administered the beers compared to the control animals showed that the beers had toxic effect on the liver (Figure 1-4). Photomicrographs of liver sections from rat in group 1 (normal control) showed normal features of the hepatic tissue. The hepatocytes (H), central vein (CV) and sinusoids (S) are normal (Figure 1). Photomicrographs from liver sections of rat administered Pito (10mL/Kg bw) showed infiltration of the central vein (CV) and distortion of regions around the central vein. The hepatocytes (H) appeared normal (Figure 2). Photomicrographs from liver sections of rat administered Burukutu-guinea corn (10mL/Kg bw) showed distortion of some periportal regions. The central vein (CV) appear mildly intact. There were evidence of some degenerative hepatocytes (dH) (Figure 3). Photomicrographs from liver sections of rat administered Burukutu-millet (10mL/Kg bw) showed infiltration and dilation of the central vein (Figure 4). There were evidence of some degenerative hepatocytes (dH). This histoarchitectural state of the liver sections of the animals agrees with the results of serum biochemical parameters evaluated in this study.

White blood cell count reduced in the animals administered pito and burukutu-millet, but increased less significantly ($p>0.05$) in the animals administered burukutu-guinea corn when compared

with the control animals (Table 2). The implication of the white blood cells result is that consumption of the local beers, especially pito and burukutu made from millet are able to alter the WBC counts and could interfere with the immune index since WBC is used for measuring immune index. Imo *et al.* [13] reported that WBC is a common immune function index that supports in defense against diseases and pathogens that affects animals, thereby promoting the immune system. White blood cells are also reported by Metcalf [21] to originate from pluripotent haemopoietic stem cells.

Administration of the beers caused an increased RBC, Hb and HCT levels in all the test groups compared to the control (Table 3). The increase in RBC and Hb levels in groups 2 and 3 were statistically significant ($p<0.05$), while the increase in HCT level showed statistically significant difference only between the normal control and group 3. This implies that consumption of pito, burukutu made from guinea corn and burukutu made from millet have blood boosting property or the ability of improving some composition of blood and may prevent certain conditions such as anaemia. The red blood cells are reported to be the animals' principal means of transporting oxygen to the body tissues through blood circulation [22]. Guinea corn and millet contain appreciable levels of carbohydrates, proteins, fat, crude fibre, iron and calcium. The nutritive constituent of guinea corn and millet may be responsible for improving the Hb and RBC levels in the test animals. The results of this study agree with the

report of Morebise *et al.* [23] that consumption of plant as foods usually promotes the synthesis of haemoglobin due to their high minerals and vitamins contents as observed in this study. The increased Hb and RBC levels in the test animals indicate that there will be adequate supply of oxygen to the body cells and could promote the immune system of the animals. The increased Hb level may have contributed to the increased RBC counts in the test animals. This is because haemoglobin level usually drops when the numbers of healthy red blood cells drop [22]. Despite the selective negative effects exhibited by the beers, they also possess the ability to improve the animals' blood system. Platelets are very important for clotting of blood. The increase in platelet counts of the test animals when compared with the control animals (Table 4) implies that the test animals may not suffer condition such as thrombocytopenia. However, if the number of platelets increase excessively, the animals may suffer thrombocytosis.

References

- [1] Kolawole, O.M., Kayode, R.M.O. and Akinduyo, B. (2007) Proximate and Microbial Analysis of Burukutu and Pito Produced in Illorin, Nigeria. *Afr. J. Biotech.* **6**(5): 587-590.
- [2] Ekundayo, J.A. (1969) The production of pito, a Nigerian fermented beverage. *J. Food Techn.* **4**: 217-225.
- [3] Odetokun, S.M. (2006) Practice Guideline Committee of the American Association for the Study of Liver Diseases and Practice Parameters Committee of the American College of Gastroenterology. *Mol. Nutr. Food Res. J.* **41**(6): 375-377.

Conclusion

This study has shown that administration of pito, burukutu-guinea corn and burukutu-millet in the test animals caused alterations and negative effect on the liver function of the male albino rats. This is evident with the increased liver-maker enzymes, reduced levels of potassium and glucose and distortions of some histoarchitectural state of the liver sections of the test animals. However, administration of the beers may not interfere negatively with Hb level and RBC count. Regular consumption of these three beers for a long duration, such as used in this study is therefore discouraged, as this may pose danger to the liver of the consumers.

List of abbreviations

AST: aspartate transaminase; ALT: alanine transaminase; WBC: white blood cell; RBC: red blood cell; Hb: haemoglobin; HCT: hematocrit; PLT: platelets; H: hepatocytes; CV: central vein; S: sinusoids; dH: degenerative hepatocytes.

Competing interests

The authors declare that they have no competing interests.

- [4] Lyumugabe, F., Gros, J., Nzungize, J., Bajyana, E. and Thonart, P. (2012) Characteristics of African traditional beers brewed with sorghum malt: a review. *Biotech. Agro. Soc. Environ.* **16**(4): 509-530.
- [5] Adewara, A.O. and Ogunbanwo, S.T. (2013) Effects of processing variables on the production of 'burukutu', a Nigerian fermented beverage. *Nature Sci.* **11**(1): 16–28.
- [6] Ogunbanwo, S.T., Adewara, A.O. and Fowoyo, P.T. (2013) Effect of fermentation by pure cultures of *Lactobacillus fermentum* and *Saccharomyces cerevisiae* as starter cultures in the production of 'burukutu'. *New York Sci. J.* **6**(1): 73–81.
- [7] Orji, M.U., Mbata, T.I., Anich, G.N. and Ahonkhai, I. (2003) The use of starter cultures to produce "pito", a Nigerian fermented alcoholic beverage. *World J. Microbiol. Biotech.* **19**: 733-736.
- [8] Ellis, W.O., Oduro, I. and Terkuu, D.M. (2005) Preliminary studies on extension of the shelf life of pito. *J. Sci. Tech.* **25**(1): 11-15.
- [9] Sanni, A.I., Onilude, A.A., Fadahusi, I.F. and Afolabi, R.O. (1999) Microbial deterioration of traditional alcoholic beverages in Nigeria. *Food Reserve Int.* **32**: 163-167.
- [10] Zhou, Y., Zheng, J., Li, S., Zhou, T., Zhang, P. and Li, H.B. (2016) Alcoholic Beverage Consumption and Chronic Diseases. *Int. J. Env. Res. Pub. Health.* **13**(6): E522.
- [11] Umaru, G.A., Tukur, I.S., Akensire, U.A., Adamu, Z., Bello, O.A. and Shawulu, A.H.B. (2014) Microflora of Kunun-Zaki and Sobo drinks in relation to public health in Jalingo Metropolis, North-Eastern Nigeria. *Int. J. Food Reserves* **1**: 16-21.
- [12] Kukoyi, A.J., Arowora, K.A., Imo, C., Mayel, M.H. and Sarduana, S.B. (2018) Effects of Various Volumes of Red Wine on Liver Function of Male Wistar Rats. *FUW Trends Sci. Tech. J.* **3**(1): 79–82.
- [13] Imo, C., Uhegbu, F.O., Imo, C.K. and Ifeanacho, N.G. (2013) Ameliorating effect and haematological activities of methanolic leaf extract of *Gongronema latifolium* in acetaminophen induced hepatic toxicity in wistar albino rats. *Int. J. Biosci.* **3**(11):183-188.
- [14] Imo, C., Uhegbu, F.O., Ifeanacho, N.G., Egbeigwe, O. and Ezekwe, A.S. (2014) Biochemical and Histological Changes Associated with Methanolic Leaf Extract of *Gongronema latifolium* in Acetaminophen-Induced Hepatic Toxicity in Wistar Albino Rats. *Int. J. Biomol. Biomed.* **4**(2): 1-7.
- [15] Murray, I.K., Mayer, P.A., Granner, O.K. and Rodwel, V. (1990) Cholesterol biosynthesis, Degradation and transport. In: *Harper's Biochemistry*. 2nd Edn. Prentice Hall International Inc, pp 240-254.
- [16] Boles, S.J., Bradley, D., Force, R.A. and Brown, B.R. (1994) The

- new dietary Fats in Health and Diseases. *J. Amr. Diab. Assoc.* **97**: 280-286.
- [17] Brown, M.S. and Goldstein, J.L. (1986) A receptor mediated pathway for cholesterol homeostasis. *Sci.* **130**: 34-47.
- [18] Austin, M.A. (1991) Plasma Triglycerides and coronary heart disease. *Arter. Thromb.* **11**: 2-14.
- [19] Uhegbu, F.O., Imo, C. and Onwuegbuchulam, C.H. (2016) Lipid lowering, hypoglycemic and antioxidant activities of *Chromolaena odorata* (L) and *Ageratum conyzoides* (L) ethanolic leaf extracts in albino rats. *J. Medicinal Plants Stud.* **4**(2): 155-159.
- [20] Nurminen, M.L., Krpela, R. and Vapattalo, H. (1998) Dietary factors in the pathogenesis and treatment of hypertension. *Annals Med.* **30**(2): 1433-1450.
- [21] Metcalf, D. (1993) The hematopoietic regulators: Redundancy or subtlety? *Blood.* **82**(1): 3515–3523.
- [22] Imo, C., Arowora, K.A., Awache, I. and Abdullahi, Z.R. (2016) Haematological Effects of Ethanolic Leaf, Seed and Fruit Extracts of *Datura metel* on Male Albino Rats. *FUW Trends Sci. Tech. J.* **1**(2): 509-512.
- [23] Morebise, O., Fafunso, M.A., Mankinde, J.M., Olayide, O.A. and Awe, E. (2002) Anti-inflammatory property of *Gongronema latifolium*. *Phytotherapy Res.* **16**: 575-577.